

## **Evaluation of intestinal health in broilers with a macroscopic scoring system for coccidiosis and bacterial enteritis.**

Dr. Hilde Van Meirhaeghe  
Poultry consultant – VETWORKS  
Knokstraat 38 – B- 9880 POEKE, Belgium

### **Summary**

There is a need for standardised methods to evaluate the intestinal health status. The macroscopic scoring system developed by Vetworks (M. De Gussem 2010) combines the evaluation of coccidiosis and dysbacteriosis or bacterial enteritis BE. The scoring system for BE was validated by histopathology ( E. Teirlynck 2011) and can be used in field conditions. The scoring system is used all over the world, in different integrations, with different feeds and different anticoccidial strategies to evaluate intestinal health in broilers. Recently the scoring system is used to evaluate the efficacy of alternative products, additives used in feed or water to reduce antibiotic treatments. The scoring system was developed for broilers, but can also be used in turkeys.

Keywords: intestinal health scoring system, bacterial enteritis

### **Resumen**

Hay una necesidad de contar con métodos estandarizados para evaluar el estado de salud intestinal. El sistema de puntuación macroscópico desarrollado por Vetworks (M. De Gussem 2010) combina la evaluación de la coccidiosis y la disbacteriosis. El sistema de puntuación de salud intestinal fue validado por histopatología (E. Teirlynck 2011) y se puede utilizar en condiciones de campo. El sistema de puntuación se utiliza en todo el mundo en diferentes integraciones, diferentes alimentaciones, diferentes programas de control de la coccidiosis para evaluar la salud intestinal en aves de corral. Recientemente se utiliza el sistema de puntuación para evaluar el efecto de productos alternativos, aditivos utilizados en la alimentación o agua para reducir los tratamientos con antibióticos. El sistema de puntuación fue desarrollado para pollos de engorde, pero también se puede utilizar en pavos.

### **Introduction**

The impressive genetic improvement of poultry growth rate has led to a modern bird with a very low feed conversion rate (FCR), high average daily gain (ADG) and low mortality. Unfortunately, this fast growth rate is often directly linked with digestive problems, such as bacterial enteritis (BE) or dysbacteriosis and even necrotic enteritis (NE). These intestinal health problems have significantly increased since the ban on meat and bone meal and the ban of antimicrobial growth promoters in Europe. BE and NE are not the same but there are some common contributing factors: poorly digestible feed with high NSP levels, damaged intestinal integrity by mycotoxines, viral agents and very often coccidiosis. Although the etiology of BE is multifactorial, it is hypothesised that, in modern broiler and turkey breeds, selected for maximal growth rate and high feed intake, abundance of unabsorbed nutrients in the gut lumen, in absence of growth promoters with antibacterial properties, causes a chain of events that exacerbates the proliferation of some clusters of bacteria that leads to a reaction of the gut wall. This reaction of the gut wall on its turn instigates some microscopic and sometimes also macroscopic changes that, as in a vicious circle, will lead to a poorer physiologic status of the intestine and decreased digestive and absorptive functions, resulting in even more nutrients in the intestinal lumen, and more substrate for bacterial growth. (Collet S. 2012)

In general, it is estimated that bacterial enteritis is responsible for around 50% to 70% of antibiotic use in most poultry veterinary practices in Europe. Very often when wet litter occurs, antibiotic treatment for bacterial enteritis is started without proper diagnosis or laboratory analyses. In dysbacteriosis there is an imbalance in the bacterial flora and not one specific bacteria is responsible, so no isolation or antibiogram is available. An important tool

to reduce antibiotic use for BE is to improve and standardise diagnostics through a universal scoring system and to set thresholds when to use an antibiotic or other alternative treatments.

### Signs of Bacterial Enteritis

In broilers, bacterial enteritis is usually observed in practice after 20 days of age. The droppings of the birds are wet, greasy or orange. A typical sign of BE on the poultry house level is increase in water intake, whereas feed intake stays at the same level or even drops, so an increase of water/feed ratio is observed. The intestines will be slightly irritated, resulting in more inflammation, expressed microscopically by increased lymphocytic infiltration and lymphocyte aggregation, and macroscopically by redness of the gut wall and a remarkable increase of the visibility of hyperaemic blood vessels on the serosal side of the intestine. The gut reacts to the changes in microbiota by producing more mucus and increasing the number of goblet cells. This results in more slimy and often watery gut contents. Histologically there is a reduction in thickness of tunica muscularis, a higher degree of villus fusion and shortening of the length of the villi. At necropsy there is a reduction of intestinal tonus, gut wall elasticity, thickness and overall strength of the intestinal wall. When cutting open the intestine it is flaccid compared to a healthy condition, where the normal tonus causes the dissected edges to curl up immediately after cutting. Another consequence of BE is ballooning of the gut: some parts of the intestine will have a visibly larger diameter than other parts, containing some amounts of liquid, greasy, slimy and/or gaseous gut contents. Grain particles might become visible from the serosal side of the unopened, translucent gut. Impaired digestion leads to an unusual high number of undigested feed particles that are typically found in the colon, rectum and excreted faeces.

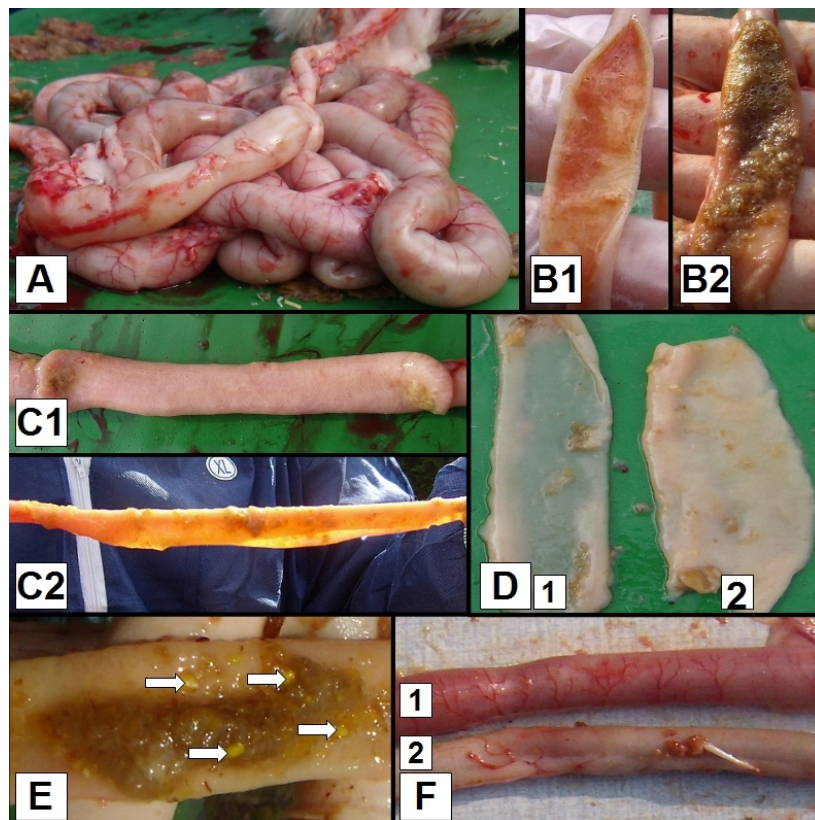
### Macroscopic scoring system for bacterial enteritis in broiler chickens and turkeys

A macroscopic scoring system to evaluate intestinal health and the level of dysbacteriosis has been developed by M. De Gussem (2010) and is broadly used. Per house 5-6 average birds are examined, on integration level a representative number of houses and farms should be sampled at different ages. For BE scoring it is important that birds have not been without feed for too long, fasting has an impact on most parameters. In practice, this evaluation is usually combined together with assessment of coccidiosis level on the same birds (Johnson and Reid 1970). An example of a scoring card combining BE scoring and coccidiosis is shown in figure 1. Ten intestinal parameters (figure 2) are assessed in a binary system (0- no lesions, 1- lesions present). The first parameter scored is ballooning of the intestines, the whole intestinal tract is evaluated. Next the intestinal tract is divided in the cranial and caudal part: Meckel's diverticulum is the separation point. Four parameters are assessed both in the cranial and the caudal part. Inflammation with prominent blood vessels visible, reduced tonus of the intestine resulting in a flaccid gut with edges that do not curl up when cut, fragility and translucency of the intestinal wall and abnormal contents. The last parameter is presence of undigested feed particles in the last part of the gut after the ileocecal junction. Maximal possible score per bird is ten. All scores of birds from the same flock or experimental unit are added and divided by the number of birds scored in order to obtain the Mean Bacterial Enteritis Score –MBES- for the flock or experimental unit.

A mean average score for BE level is calculated for a house, a farm or an integration. Such evaluation schema allows to set certain threshold levels for antibiotic treatment, where for example for score 0-2 no treatment is applied, with score 3-5 only non-antibiotic alternative treatments are allowed and with score 6-10 only narrow spectrum gram- positive antibiotics are used.

Farm:	Coccidiosis			Bacterial Enteritis										
House:				Overall	Cranial				Caudal				Overall	
Age:	Eimeria			Gut ballooning	Inflammation/ blood vessels dilated	Flaccid	Abnormal Contents	Thickness/ Translucency/ Fragility	Inflammation/ blood vessels dilated	Flaccid	Abnormal Contents	Thickness/ Translucency/ Fragility	Undigested feed	Date:
Chick	acervulina	maxima	tenella											BES
1														
2														
3														
4														
5														
6														
MLS				Previous anticoccidial program :										
TMLS		TMBES		Current anticoccidial program :										

**Figure 1:** Scoring card for intestinal health in broilers, combining lesion scoring for coccidiosis and Bacterial Enteritis



**Figure 2 .** Macroscopic dysbacteriosis score system parameters. **A.** Overall gut ballooning; **B.** Content of the intestinal tract, **1.** Mucoïd, orange intestinal content, **2.** Foamy intestinal content; **C.** Tonus of the intestinal tract, **1.** Good tonus, **2.** Lack of tonus; **D.** Macroscopically visible thickness of the intestinal tract, **1.** Macroscopically thin intestinal tract, **2.** Intestinal tract with normal thickness; **E.** Undigested particles in the colon (arrows); **F.** Inflammation of the gut, **1.** Inflammation, **2.** No inflammation.

### Coccidiosis scoring system

The scoring system for coccidiosis by Johnson and Reid (1970) was originally developed for experimental studies, but has been widely used in field conditions to evaluate infection pressure based on macroscopic visible lesions caused by *Eimeria* species. Only those species that caused specific lesions can be scored *E. acervulina*, *E. maxima*, *E. tenella*, in broilers and *E. necatrix* and *E. brunetti* in older birds. A limitation of the system is that *E. mitis* and *E. praecox*, although the former is quite pathogenic, are disregarded because they do not cause typical lesions. Lesion scoring still remains the most frequently applied diagnostic method today, because the correlation between lesion scores and performance is believed to be stronger than with OPG – oocysts per gram faeces- but still there is a difficult appreciation of the level of lesions towards impact on performance, especially at subclinical levels.

Generally, it is agreed upon that from the species recognized in broiler chickens, the most pathogenic are *E. acervulina*, *E. maxima* and *E. tenella*. The latter is, amongst broiler farmers, the best known. It infects the caeca and because of its deep development in the mucosa and subsequent wide-spread damage with distinct gross lesions and loss of blood in the faeces, it is easily recognized. On the other hand, when performing field necropsies on a larger scale, *E. tenella* appears to be the least prevalent of the three species mentioned. Also, the damage is being limited to the caeca, relative less important parts of the gut with regard to digestion and absorption, thus effects on growth and feed conversion rate. *E. acervulina* and *E. maxima*, both much more prevalent, are less perceived to be related with clinical coccidiosis in the field. *E. acervulina* is causing white lesions on the mucosal side of the duodenum and in heavier infections also more caudal, interfering even with the ability for *E. maxima* to develop. *E. maxima* causes petechiae most visible on the serosal side in the midgut. The individual scores ( from 0-4) for all the species are compiled for a certain number of birds (e.g. 5-6) per flock resulting in a Total Mean Lesion Score (TMLS). When evaluating the results it is important to keep in mind the pathogenicity of each species to decide if treatment is needed or the coccidiosis control program is inadequate. All infection with *Eimeria*, even subclinical, requires invasion and destruction of host cells, and will activate the immune system. For this process nutrients are used that cannot be converted to meat production, resulting in loss of performance. Because coccidiosis causes loss of integrity of the mucosa and an inflammatory response, it is a major contributing factor to bacterial enteritis. Therefore it is very logic to include the lesion scoring for coccidiosis, when assessing general intestinal health status.

### Conclusions

A standardized scoring procedure for bacterial enteritis in combination with coccidiosis has been developed and validated by histopathology. The system can be used to evaluate the intestinal health in general and the effect of additives in water or feed, changes in feed or management strategies. Results can be compared with historical data and industry averages, to support decision making in an evidence based way, to improve intestinal health in poultry production.

### References

- Collet, S. R(2012) Why the avian enteric tract responds the way it does. Arkansas Nutritional Conference 5th September 2012
- De Gussem, M. (2010). Macroscopic scoring system for bacterial enteritis in broiler chickens and turkeys. WVPA Meeting 01/04/2010. Merelbeke, Belgium.
- Teirlynck, E., De Gussem, M., Dewulf, J., Haesebrouck, F., Ducatelle, R., Van Immerseel, F., (2011). Morphometric evaluation of "dysbacteriosis" in broilers. Avian Pathology 40(2):139-144
- Johnson, J. , Reid W. ( 1970) Anticoccidial drugs: Lesion scoring techniques in battery and floor-pen experiments with chickens. Experimental Parasitology, Volume 28, Issue 1, August Pages 30-36